doi:10.1111/imj.14268

REVIEW

Front-line management of indolent non-Hodgkin lymphoma in Australia. Part 2: mantle cell lymphoma and marginal zone lymphoma

Chan Y. Cheah,[1,2,3] Stephen Opat,[4,5] Judith Trotman [6,7] and Paula Marlton [8,9]

[1]Department of Haematology, Sir Charles Gairdner Hospital, Nedlands, [2]Department of Haematology, Pathwest Laboratory Medicine WA, [3]Medical School of Pathology and Laboratory Medicine, University of Western Australia, Perth, Western Australia, [4]Clinical Haematology and School of Clinical Sciences, Monash Health, and [5]Department of Medicine, Monash University, Melbourne, Victoria, [6]Department of Haematology, Concord Hospital, and [7]Department of Medicine, University of Sydney, Sydney, New South Wales, and [8]Division of Cancer Services, Clinical Haematology, Princess Alexandra Hospital, and [9]University of Queensland School of Medicine, Brisbane, Queensland, Australia

Key words
mantle cell lymphoma, marginal zone B-cell lymphoma, disease management, rituximab, bendamustine.

Correspondence
Paula Marlton, Division of Cancer Services, Clinical Haematology, Princess Alexandra Hospital, 199 Ipswich Road, Woolloongabba, Qld 4102, Australia.
Email: paula.marlton@health.qld.gov.au

Received 15 August 2018; accepted 16 February 2019.

Abstract

Mantle cell lymphoma (MCL) and the marginal zone lymphoma (MZL) subtypes (nodal MZL, extra-nodal MZL of mucosa-associated lymphoid tissue (MALT lymphoma) and splenic MZL) are uncommon lymphoma subtypes, accounting for less than 5–10% of all non-Hodgkin lymphoma. The evidence base for therapy is therefore limited and enrolment into clinical trials is preferred. Outcomes for patients with MCL have been steadily improving mainly due to the adoption of more intense strategies in younger patients, the use of rituximab maintenance and the recent introduction of bendamustine in older patients. MZL is a more heterogeneous group of cancer with both nodal, extra-nodal and splenic subtypes. Extranodal MZL may be associated with autoimmune or infectious aetiologies, and can respond to eradication of the causative pathogen. Proton pump inhibitor plus dual antibiotics in *Helicobacter pylori* positive gastric MALT lymphoma is curative in many patients. Watchful waiting is appropriate in most patients with asymptomatic advanced stage disease, which tends to behave in a particularly indolent manner. Other options for symptomatic disease include splenectomy, chemoimmunotherapy with rituximab and, more recently, targeted therapies.

Introduction

Part 1 of this two-part series on indolent non-Hodgkin lymphoma (NHL) discussed the front-line management of follicular lymphoma, the second most common subtype of NHL. In this second article, we discuss the less frequently encountered subtypes mantle cell lymphoma (MCL) and marginal zone lymphoma (MZL). Waldenströms macroglobulinaemia was the subject of recently published comprehensive guidelines.[1]

The Australian Institute of Health and Welfare reports an age-standardised incidence rate for NHL of 19.4 per 100 000 person–years for 2013; data for subtypes are not reported separately.[2] Older Australian incidence data, from 1997–2006, have been published for MCL and

Funding: Janssen-Cilag Australia. J. Trotman reports research funding from Janssen, Roche, Celgene, Pharmacyclics and Beigene. C. Y. Cheah reports grants and advisory fees from Gilead, grants and speaker honoraria from Roche, advisory fees from Janssen and grants from Celgene. P. Marlton reports advisory fees, and/or speaker honoraria from Novartis, Roche, Janssen, Celgene, Abbvie, Gilead and Pfizer. S. Opat reports research funding, advisory fees, speaker fees, honoraria and provision of subsidised drugs from Roche, Janssen and Celgene, research funding, advisory fees, speaker fees and honoraria from Takeda Pharmaceuticals and Novartis, research funding, advisory fees and honoraria from Abbvie and Gilead, advisory fees and travel support from Bristol-Myers Squibb, research funding from BeiGene and advisory fees from Sanofi and Mundipharma.
Conflict of interest: Administrative and medical writing support was provided by Ms Vasugi Sanjayan (Allori Pty Ltd, Australia) and was funded by an independent grant from JANSSEN-CILAG Australia. The sponsor had no involvement in content development or approval. The authors were responsible for all content and editorial decisions, and received no honoraria related to the development of this manuscript.

© 2019 Royal Australasian College of Physicians

MZL, showing annual age-standardised rates of 0.5 per 100 000 person–years for both.[3]

Mantle cell lymphoma

MCL accounts for about 5% of all NHL and is approximately three times more common in men than in women.[4] The majority present at an advanced stage with a median age at diagnosis of 68 years.[5,6] Although most cases are clinically aggressive, up to one-third of patients have an indolent presentation where initial therapy can be deferred until progression.[5,7] These cases are characterised by non-nodal presentation (leukaemic disease and splenomegaly) and feature IgVH hypermutation and genetic stability. CD200, positive in only 4% of MCL cases overall, may be a potential marker for these cases.[8]

Diagnosis and staging

Around three-quarters of patients with MCL present with generalised lymphadenopathy and extra-nodal involvement in bone marrow, gastrointestinal tract and peripheral blood is frequent.[6] Excisional lymph node biopsy is preferred over core biopsy to secure diagnosis.[9] Most cases display a monomorphic neoplastic lymphoid infiltrate with a variety of histologic patterns, including nodular, diffuse, pleomorphic and blastoid, the latter two being more clinically aggressive.[10] By immunophenotyping, typically CD19, CD20, CD22 CD43, CD79a, CD5 and FMC7 are positive, while CD23, CD10, CD200 and BCL6 are negative.[10] MCL is characterised by t(11;14)(q13;q32) translocation resulting in cyclin D1 overexpression and demonstration of t(11;14)(q13;q32) by FISH or cyclin D1 by immunohistochemistry is required to secure the diagnosis. However, rare cases of cyclin D1 negative MCL have been reported, and *SOX11* expression and rearrangements of *CCND2* may then be of diagnostic utility.[9–11] Ki-67 ≥30% is adversely prognostic for survival, independent of histology and growth pattern.[4,12]

Staging is carried out using the Lugano classification (Table 1),[9] and recommended procedures include physical examination, peripheral blood examination, including morphologic assessment and flow cytometry to detect leukaemic disease, computed tomography (CT) scan, and bone marrow aspirate and biopsy. Positron emission tomography (PET) is not mandatory, but useful to confirm stage I/II disease.[6] Endoscopy and blind biopsy can reveal gastrointestinal involvement in up to 95% of cases[4]; however, this rarely changes management and should be reserved for patients with apparent stage I/II disease or gastrointestinal symptoms. The combined MCL International Prognostic Index (MIPI-c), integrating the MIPI (age, performance status, lactate dehydrogenase (LDH) level, white blood cell count) and MIPI biologic (MIPI-b, comprising MIPI and the Ki-67 index), is useful for prognostication (Table 2).[12]

Table 1 Revised staging system for primary nodal lymphomas[9]

Stage	Involvement†	Extranodal (E) status
Limited		
I	Single node; or group of adjacent nodes	Single extranodal lesions without nodal involvement
II	≥2 nodal groups on same side of diaphragm	Stage I or II by nodal extent with limited contiguous extranodal involvement
II	bulky‡	II as above with 'bulky' disease
Not applicable		
Advanced		
III	Nodes on both sides of the diaphragm; or Nodes above the diaphragm with spleen involvement	Not applicable
IV	Additional non-contiguous extralymphatic involvement	Not applicable

†Extent of disease is determined by PET-CT for avid lymphomas and CT for non-avid histology. Nodal tissue includes tonsils, Waldeyers ring and spleen. ‡Whether stage II bulky disease is treated as limited or advanced depends on histology and prognostic factors. CT, computed tomography; PET, positron emission tomography.

Current treatment approaches

There is no international consensus regarding the optimal induction therapy for patients with MCL. Although

Table 2 Combined MIPI (MIPI-c)-defined prognostic groups

MIPI risk group†	Ki-67 index	MIPI-c score‡	5-year OS
Low (0)	<30% (0)	0	85%
	≥30% (1)	1	72%
Intermediate (1)	<30% (0)		
	≥30% (1)	2	43%
High (2)	<30% (0)		
	≥30% (1)	3	17%

†The MIPI risk group is calculated using the following formula: (0.03535 × age (years)) + 0.6978 (if ECOG >1) + (1.367 × log 10(LDH/ULN)) + (0.9393 × log 10(white cells × 10^9/L)). A raw score <5.7 indicates low-risk disease (MIPI-c score = 0–1); 5.7–6.2 indicates intermediate risk (MIPI-c score = 1–2), and ≥ 6.2 high risk (MIPI-c score = 2–3). ‡MIPI-c is derived from a combination of the MIPI risk group score (0–2) and Ki-67 index score (0 if Ki-67 <30; 1 if Ki-67 ≥30). ECOG, Eastern Cooperative Oncology Group; LDL, lactate dehydrogenase; MCL, mantle cell lymphoma; MIPI, MCL International Prognostic Index; OS, overall survival; ULN, upper limit of normal.

© 2019 Royal Australasian College of Physicians

MCL is typically initially chemosensitive, most patients eventually experience relapse.[5]

Stages I–II

MCL presenting with truly limited stage disease is rare (<5% of all patients) and has more favourable outcomes.[5] The largest study included 179 patients (75% head and neck) who received either chemotherapy, chemo-radiation or radiation alone.[13] The 10-year overall survival (OS) rates were similar at 69, 62 and 74% respectively and 10-year freedom from progression rates were also similar at 46, 43 and 31%. While radiation monotherapy results in long-term disease control in only around one-third of patients, it is a reasonable option for elderly or frail patients. The optimal treatment approach is therefore unclear, with decisions influenced by patient age and fitness, expected toxicity, disease bulk and number of nodal sites.

Stages III and IV

Patient age and comorbidities determine the therapeutic approach in stage III–IV disease and enrolment into clinical trials subject to availability and eligibility is preferred. A suggested approach for advanced stage MCL in the Australian healthcare setting is outlined in Figure 1. The intent of treatment is to alleviate symptoms, induce remission and prolong life. The incorporation of high-dose cytarabine, autologous stem cell transplant (ASCT) and rituximab maintenance have all resulted in incremental improvements in survival in the frontline setting.[6]

Patients with asymptomatic disease can be safely observed, without compromising OS, from time of treatment initiation.[14] Observation is appropriate for patients with Ki-67 <30%, non-blastoid/pleomorphic histology, maximum tumour diameter <3 cm, normal LDH/β_2-microglobulin and no B symptoms or cytopenias.[6]

First line treatment: fit for intensive therapy. For fit patients, usually <65 years, regimens containing high-dose cytarabine ± ASCT have achieved the best results.[15–18]

In the EMCLN 'Younger' study, Hermine *et al.* randomised 497 patients under 65 years with treatment-naïve MCL to six cycles of either R-CHOP (rituximab, cyclophosphamide, doxorubicin, vincristine and prednisone) or R-CHOP alternating with DHAP (dexamethasone, cytarabine and cisplatin), followed by ASCT.[16] After a median follow up of 6.1 years, the time to treatment failure was longer in the R-CHOP/DHAP group (median 9.1 vs 3.9 years; HR, 0.56 (P = 0.038)) with increased grade ≥3 haematologic toxicity and neutropenic fever. There was no difference in OS.

Le Gouill *et al.* performed a phase III study in which 299 patients aged <66 were treated with four cycles of R-DHAP (CHOP reserved for patients not in complete remission (CR)) and ASCT then randomised to either rituximab maintenance (every 2 months for 3 years) or observation.[17] Few patients actually required the anthracycline after DHAP; 257 patients received ASCT and 240 patients were randomised to either maintenance rituximab or observation. Patients who received

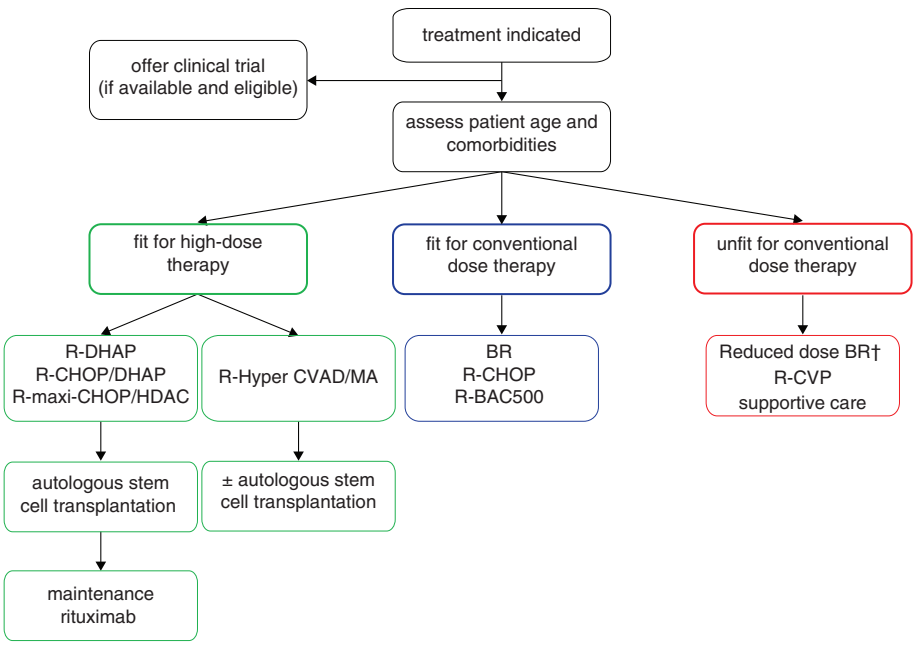

Figure 1 A suggested approach for treating advanced stage mantle cell lymphoma in the Australian healthcare setting. †Bendamustine 50–70 mg/m^2. R-DHAP, rituximab, dexamethasone, high dose cytarabine plus cisplatin (could be substituted, if required, with the less nephrotoxic carboplatin or oxaliplatin); R-CHOP, rituximab, cyclophosphamide, doxorubicin, vincristine plus prednisone; R-maxi-CHOP/HDAC, alternating cycles of R-CHOP and high-dose cytarabine; R-HyperCVAD/MA, rituximab with alternating cycles of fractionated cyclophosphamide, vincristine, doxorubicin plus dexamethasone, and high-dose methotrexate plus high-dose cytarabine; R-BAC50, rituximab, bendamustine plus intermediate-dose cytarabine (500 mg/m^2).

© 2019 Royal Australasian College of Physicians

rituximab maintenance had superior 4 year rates of event-free survival (EFS 79 vs 61%, $P = 0.001$) and OS (89 vs 80%, $P = 0.04$).

Other effective induction regimens shown in phase II studies to result in durable remissions are rituximab with alternating cycles of maxi-CHOP and high-dose cytarabine (Nordic MCL2),[15] and rituximab with alternating cycles of fractionated cyclophosphamide, vincristine, doxorubicin and dexamethasone (hyper-CVAD) and high-dose methotrexate and cytarabine (MA).[18,19]

ASCT following high-dose induction has been included in most phase II and III studies in transplant eligible MCL patients,[16,17,20] following demonstration of its superiority over interferon maintenance in a randomised trial.[21] The EBMT/EMCLN consensus statement recommends consideration of ASCT as the first consolidation strategy in patients fit for high-dose therapy,[22] as do the recent ESMO guidelines.[4] While limited available evidence suggests consolidation with allogeneic SCT provides progression free survival (PFS)/OS similar to ASCT we do not advocate its use outside clinical trials due to the greater risk of transplant-related mortality and graft-versus-host disease.[23–26] High-dose chemotherapy with autologous stem cell transplant in fit patients is generally best performed as initial therapy rather than in relapsed or refractory disease.[4]

Even with intensive therapy there appears to be a continuous pattern of relapse without a plateau in survival as evidenced by the 15-year follow up of the Nordic MCL2 and MD Anderson R-HCVAD/MA phase II trials.[19,27]

First line treatment: fit for conventional dose therapy. In older patients suitable for conventional dose chemoimmunotherapy, choices include bendamustine-rituximab (BR) and R-CHOP. The randomised Stil-NHL[28] and BRIGHT[29] studies, which included patients with MCL, suggested a PFS advantage for BR (over R-CHOP and R-CHOP/rituximab, cyclophosphamide, vincristine, prednisone (R-CVP) respectively) in the absence of rituximab maintenance, although the former study was a non-inferiority design. R-CHOP followed by rituximab maintenance was established as a reasonable standard of care in the EMCLN Elderly study.[30] Rituximab maintenance is currently not reimbursed by the Pharmaceutical Benefits Scheme (PBS) in Australia for MCL. Thus, given the relatively favourable toxicity profile, BR is a reasonable initial therapy in fit, transplant-ineligible patients. No survival advantage has been shown for rituximab maintenance after BR initial therapy in older patients with MCL.[31]

The addition of intermediate dose cytarabine (500 mg/m^2) to BR (bendamustine 70 mg/m^2) resulted in encouraging efficacy in a small phase II study of patients over 60 yrs. who were unfit for transplant. Forty-two out of 57 patients (76%) were free from progression after a median follow up of 35 months.[32] The addition of cytarabine to bendamustine increases haematologic toxicity and whether it improves outcomes is not yet definitively proven; as such, this regimen should only be considered for those with low rates of comorbidity and adequate organ function.

Cytarabine-based chemoimmunotherapy (R-hyper-CVAD/R-MA; R-CHOP/R-DHAC) significantly improved OS and PFS over a median follow up of 40 months without ASCT in patients >60 years (median age 69 years).[33] The use of this treatment in older patients is based on extension of the experience in younger patients where incorporation of cytarabine significantly improves outcomes; however, the toxicity is an important consideration. Of note, the Nordic MCL5 trial examining the combination of cytarabine and rituximab was abandoned early after poor outcomes were noted in four of the first five patients enrolled.[34]

First line treatment: unfit for conventional dose therapy. Frail elderly patients may be offered reduced dose BR (50–70 mg/m^2) or R-CVP with consideration given to abbreviating therapy to four cycles if significant toxicities occur. In contrast to follicular lymphoma, rituximab monotherapy and radioimmunotherapy have limited efficacy and should be avoided.[4]

Relapsed disease

There is no standard therapy for patients with relapsed/refractory MCL and enrolment to clinical trials should be prioritised. Young/fit patients with chemosensitive disease may be considered for potentially curative allogeneic SCT.[35] Salvage therapy with non-cross resistant chemotherapy (e.g. DHAP following CHOP or vice versa) in relapse under 12–24 months can produce high overall response rate (ORR), but disease control is brief (median PFS <2 years).[6] Bendamustine with rituximab has high ORR and durable disease control,[36] but is currently not PBS-reimbursed in the relapsed/refractory setting in Australia.

Non-chemotherapy options in patients with early relapse, chemo-refractoriness and not transplant-eligible include Brutons tyrosine kinase (BTK) inhibitors (such as ibrutinib and other second generation agents), lenalidomide, temsirolimus and bortezomib. Of these, only ibrutinib is reimbursed by the PBS for use in relapsed/ refractory MCL. Pooled analysis of the SPARK, RAY and PCYC-1104 studies of treatment with ibrutinib in early relapsed/refractory MCL showed 26.5% of patients achieved a CR over median follow up of

© 2019 Royal Australasian College of Physicians

3.5 years, 26% were progression free at 3 years, and 45% were alive at 3 years (median PFS, 13 months; median OS, 26.7 months).[37] The results of the combination of ibrutinib and venetoclax in a small phase 2 study appear to indicate synergistic activity with a 71% PET-CT CR rate at 16 weeks and high rates of MRD negativity,[38] and have led to an ongoing global phase III randomised study comparing ibrutinib/venetoclax to ibrutinib/placebo (SYMPATICO; NCT03112174).

Marginal zone lymphoma

Collectively, MZL is the third most common B-cell lymphoma and the second most common indolent lymphoma (5–17% of all NHL).[39,40] Three distinct subtypes are recognised. Extra-nodal MZL of mucosa-associated lymphoid tissue (MALT lymphoma) accounts for 50–70% of cases, while nodal MZL represents around 10%, and splenic MZL approximately 20% of MZL cases.[10,41]

MALT lymphoma

MALT lymphoma can arise in virtually all tissues where chronic antigenic stimulation by infectious pathogens or autoimmunity can induce inflammatory lymphoid populations.[41] The stomach is the most frequent site with gastric MALT accounting for at least one third of patients.[42] Other common sites include the ocular adnexa, salivary gland, skin, conjunctiva, lung, thyroid and breast, with potentially diverse site-specific aetiologies (Table 3).[40] The strongest evidence for a specific aetiologic pathogen relates to *Helicobacter pylori*-induced chronic gastritis implicated in around two thirds of gastric MALT cases. Autoimmune diseases such as Sjogren syndrome and Hashimoto thyroiditis are associated with increased risk of MALT lymphoma of the salivary gland and thyroid respectively. Clinical presentation of MALT lymphoma varies widely according to the site(s) of involvement. Typically, they are biologically indolent and patient outcomes are generally favourable.[39]

Table 3 Pathogens implicated in marginal zone lymphoma (MZL)

Pathogen	Type of MZL lymphoma
Helicobacter pylori	Gastric MALT[41]
Chlamydophila psittaci	Ocular adnexal MALT[41]
Campylobacter jejuni	Small intestinal MALT[41]
Borrelia burgdorferi	Cutaneous MALT[41]
Hepatitis C virus	Nodal and splenic MZL[60]

MALT, mucosa-associated lymphoid tissue.

Diagnosis and staging

MALT lymphomas characteristically remain localised for prolonged periods although multi-focal single organ involvement and systemic dissemination can occur in up to 25% of cases (more likely with non-gastric sites).[41,43] Patients with bone marrow involvement (approximately 20%) or nodal dissemination have a worse prognosis[41] and require different therapeutic strategies from patients with localised disease.[42] Thus careful staging is required and the diagnostic work up should be tailored according to the site involved and any possible underlying infectious or autoimmune causes.[41] Endoscopic ultrasound is recommended for staging of gastric MALT. The MALT international prognostic index (MALT-IPI) is useful for prognostication.[44]

Current treatment approaches

Gastric MALT lymphoma. In patients positive for *H pylori* infection, standard eradication therapy with a proton pump inhibitor plus dual antibiotics should be instituted. *H pylori* eradication alone is reported to result in localised gastric MALT lymphoma regression in 75% of cases.[41] Re-testing at 2 months with a breath test, following cessation of proton pump inhibitors for at least 1 month, should be undertaken to ensure eradication before re-assessing the lymphoma status endoscopically 3 months after eradication.[42,45]

For patients with localised disease who are *H. pylori* negative, empiric eradication therapy may still be beneficial in a significant proportion of patients.[46] Similarly, clarithromycin therapy has resulted in meaningful response rates in some patients with gastric MALT lymphoma (and other subtypes).[47]

For patients who have failed eradication therapy, there is no clear consensus on the best treatment approach. Involved site radiotherapy is favoured by many, with excellent reported outcomes using moderate doses (24–30 Gy over 3–4 weeks).[45] One study which included patients with localised gastric or non-gastric MALT lymphoma reported 10-year overall and recurrence-free survival rates of 87 and 76% respectively, with cause-specific survival of 98%.[48] Other treatment options include chemoimmunotherapy, most commonly R-chlorambucil[49] and R-CVP[42]. Gastrectomy has been used historically and although potentially curative is often associated with significant long-term morbidity and is rarely considered in current practice.

Non-gastric MALT lymphoma. Patients with localised disease in other sites associated with a postulated causative pathogen (Table 3) should be considered for

© 2019 Royal Australasian College of Physicians

eradication therapy, although the aetiologic relationship and outcomes following eradication are less well established. Response rates of around 50% have been reported for ocular adnexal MALT associated with *Chlamydophila psittaci* in patients treated with prolonged doxycycline or clarithromycin.[50] However, the specificity of PCR testing in this setting is unknown and disease regression using antibiotics has been reported in 6 of 16 *C. psittaci*-negative cases.[51] Thus testing and an empiric trial of eradication is a reasonable approach. Data regarding response rates to antibiotics in the other subtypes are scant and no firm conclusions can be drawn. Local radiotherapy is often the treatment of choice for localised non-gastric MALT lymphoma.[52]

Advanced stage disease. Advanced stage MZL of MALT type is incurable and the usually indolent biology allows for a watch and wait approach in most patients. When treatment is required, systemic chemoimmunotherapy has been used successfully. The addition of rituximab to chlorambucil improved outcomes compared to either agent alone.[49] Bendamustine plus rituximab has been reported as safe and effective in a phase 2 trial of 60 patients with a median follow up of 43 months.[53] Event-free survival was 93% (95% CI, 84–97%) at 2 years and 88% at 4 years.

Many trials of other agents effective in B-cell lymphomas have included a few patients with MALT lymphoma; however, the numbers are insufficient to draw conclusions and all such agents remain investigational. Lenalidomide and bortezomib have shown activity in phase 2 studies.[54,55] Ongoing trials recruiting patients with MZL of MALT type should always be considered for patients with this uncommon disease.

Nodal MZL

Nodal MZL is the least common of all the MZLs representing approximately 10% of MZLs and <2% of all NHL.[40,56] The median age at presentation is 60 years with both genders equally affected.[57] The understanding of nodal MZL has been hampered by its rarity, with therapeutic strategies largely based on data from follicular or small lymphocytic lymphoma. In common with these disorders, the disease generally behaves in an indolent fashion and is often disseminated at presentation. Histologic transformation is reported in 3–15% of patients with nodal MZL and is often associated with a poor outcome.[58] In a large retrospective series, the crude incidence of histologic transformation was 34/453 (7.5%) with elevated serum LDH, >4 nodal sites and failure to achieve CR associated with increased risk of transformation by multivariable competing risk regression analysis.[59] While there is an association with hepatitis C infection (Table 3),[60] a history of autoimmunity is less common than with other forms of MZL.[61]

Like other indolent NHL, nodal MZL is largely incurable with a course characterised by periods of remission and relapse. The largest dataset informing prognosis of patients with nodal MZL is the US SEER dataset from 4724 patients.[57] While the 10-year overall survival of patients with nodal MZL is only 44.3%, nearly half the recorded deaths are unrelated to lymphoma, being mainly cardiovascular disease and other malignancies.[62] A reduction in lymphoma related death in cases diagnosed after 2000 was also noted possibly due to the introduction of rituximab.[62,63]

Diagnosis and staging

Peripheral lymphadenopathy involving the head and neck lymph nodes is common at presentation, with up to one-third of patients having bulky tumours (>5 cm) and about half having stage III/IV disease (Table 1).[61] Approximately 10% of patients will present with an IgM paraprotein,[56] which can result in the diagnosis being confused with Waldenströms macroglobulinaemia. The absence of *MYD88* L265P mutation (a feature of Waldenströms macroglobulinaemia) supports the diagnosis of NMZL although it may also be observed in roughly 15% of SMZL.[64]

Nodal MZL demonstrates similar cytologic, immunophenotypic and genetic features to both splenic and extranodal MZL which may result in diagnostic difficulty, particularly in cases with involvement of spleen or extranodal sites.[56]

Validated prognostic scoring systems are lacking in nodal MZL, with conflicting data regarding the applicability of FLIPI.[63,65] Increased age and advanced stage have however been associated with adverse prognostic impact.[62]

Current treatment approaches

The standard therapy for nodal MZL is yet to be defined with many centres employing strategies used in follicular lymphoma. Patients with localised disease respond well to radiotherapy, and those with minimally symptomatic, low tumour burden, advanced stage disease are suitable for watchful waiting.[56] Reports of regression of MZL with eradication of hepatitis C infection support this strategy as an initial approach in hepatitis C infected patients.[66,67] Patients with disseminated disease and high tumour burden can be treated with chemoimmunotherapy.[57]

Chemoimmunotherapy. Despite the lack of prospective data, chemoimmunotherapy with rituximab is generally considered standard treatment for patients with

© 2019 Royal Australasian College of Physicians

symptomatic advanced stage disease. As patients may require treatment over an extended period, consideration should be given to limiting prolonged or repeated exposure to alkylating agents and purine analogues to minimise the risk of myelodysplasia and the impact on the ability to harvest stem cells for transplant.

Various first line chemoimmunotherapy regimens have been examined, including R-CVP,[68] R-CHOP,[28] fludarabine and rituximab (FR),[69] fludarabine, cyclophosphamide and rituximab (FCR)[70] and BR[28,71] (Table 4). R-CHOP and BR were associated with similar progression free survival (47.2 months and 57.2 months respectively, P = 0.3249) in various MZL subtypes, including nodal MZL.[28] While data on BR and R-CHOP in nodal MZL are limited, the available studies confirm the high tolerability, response rates and durability of these combinations. The toxicity and poor tolerability of fludarabine-based regimens particularly in older patients have rendered them largely of historic interest.

There are limited data on the role of autologous stem cell transplantation as front line therapy in NMZL; however, it may be a useful strategy in selected patients with chemo-sensitive disease in the relapsed setting.[72]

Genetic studies of NMZL have identified actionable mutations involving B-cell receptor, JAK/STAT, NF-κB, NOTCH and Toll-like receptor signalling pathways.[73] Several agents targeting these (bortezomib, everolimus, idelalisib, copanlisib, ibrutinib, zanubrutinib) are currently under investigation, mainly in patients with relapsed and refractory disease.

Splenic MZL

Splenic MZL (SMZL) makes up less than 2% of all lymphoid malignancies, and 20% of all MZL. It is usually indolent, with a median survival of 8–10 years, but can transform to diffuse large B-cell lymphoma in ~5–10%.[40,74] Approximately one-third of patients have no symptoms, and a watch and wait approach has no adverse impact on overall survival.[75]

Diagnosis and staging

Distinguishing SMZL (also referred to as splenic lymphoma with villous lymphocytes) from other indolent B-cell lymphoproliferative disorders is challenging, with a definitive diagnosis relying on spleen histology.[74] However, in most patients the diagnosis can be suggested by the characteristic morphology of circulating lymphoma cells with polar villous cytoplasmic projections and round nucleus (in contrast to the larger hairy cell leukaemia (HCL) cells with evenly spaced circumferential cytoplasmic projections and an oval or bean shaped nucleus).[10]

Immunophenotyping of circulating or bone marrow lymphocytes demonstrates IgM +/− IgD, CD19, CD20, CD22 and BCL-2 expression. Lack of CD5 (usually), CD23, CD25 and CD103 along with cyclin D1 negativity assist in excluding chronic lymphocytic leukaemia, mantle cell and, importantly, HCL which also causes prominent splenomegaly. In common with nodal MZL an IgM paraprotein may occur and *MYD88* mutation testing can help distinguish from Waldenström macroglobulinaemia.[76] A small fraction of patients harbour hepatitis C infection (Table 3), which should be treated as tumour responses are frequent.[66]

Splenic hilar lymphadenopathy occurs in 25% of SMZL, but peripheral lymphadenopathy is uncommon.[77,78]

While most patients present with splenomegaly and lymphocytosis (often noted incidentally), cytopenias, most commonly due to hypersplenism, is found in

Table 4 Chemoimmunotherapy regimens in nodal MZL

Treatment	Median duration of follow up	Progression-free survival	Overall survival	Study
R-CVP 3-weekly for six or eight cycles (n = 40)	38.2 months	At 3 years: 59%	At 3 years: 95%	Kang *et al*.[68] 2012
R-CHOP 3-weekly for up to six cycles (n = 253) versus BR 4-weekly for up to six cycles (n = 261)	45 months	R-CHOP: 31.2 months median (15.2–65.7) BR: 69.5 months median (26.1 to not reached) HR, 0.58; 95% CI 0.44–0.74; P < 0.0001	Not assessed	Rummel *et al*.[28] 2013
FR 4-weekly for up to six cycles (n = 26; only 58% completed)	3.1 years (1.0–4.7)	79.5% (95% CI, 63.4–95.6%)	87.4% (95% CI, 74–99%)	Brown *et al*.[69] 2009
FCR 4-weekly for up to 6 cycles (n = 46; 87.2% completed)	40.9 months	90.1% (95% CI, 75.5–96.2%)	97.4% (95% CI, 83.2–99.6%)	Ferrario *et al*.[70] 2012

BR, bendamustine plus rituximab; FCR, fludarabine, cyclophosphamide plus rituximab; FR, fludarabine plus rituximab; R-CHOP, rituximab, cyclophosphamide, doxorubicin, vincristine plus prednisone; R-CVP, rituximab, cyclophosphamide, vincristine plus prednisone.

© 2019 Royal Australasian College of Physicians

~25%.[77] Autoimmune haemolytic anaemia and other autoimmune phenomena can occur. SMZL staging is completed with CT. PET is seldom contributory unless transformation is suspected.[74]

Current treatment approaches

A watch and wait approach is used with follow up every 3–6 months, and treatment recommended only in the presence of symptomatic splenomegaly, cytopenia, systemic symptoms or progressive nodal disease.[74,75] Treatment options in SMZL include splenectomy, rituximab monotherapy, chemotherapy, chemoimmunotherapy (with rituximab) for disseminated disease and high-grade transformation and new targeted therapies.[74]

Splenectomy. Splenectomy was the mainstay of therapy for decades before rituximab monotherapy became the popular choice for this patient population, which is mostly elderly with comorbidities. Nonetheless, splenectomy removes a significant burden of disease, ameliorating abdominal discomfort and resolving cytopenias due to splenic sequestration, as opposed to those due, less commonly, to extensive marrow involvement.[74] After surgery, patients can remain free from treatment for many years. One additional advantage of splenectomy is that a definitive diagnosis of SMZL can be established.[74] Short-term perioperative complications of splenectomy can be reduced with the laparoscopic approach and prophylaxis against venous thromboembolism. The long-term risk of infections, specifically with encapsulated bacteria, can be minimised with vaccinations at least 2 weeks before elective splenectomy.[74] Oral amoxicillin use in accordance with the Spleen Australia infection prophylaxis guidelines, accessible at https://spleen.org.au/VSR/information.html, should be followed.[79]

Chemoimmunotherapy. Combination rituximab chemotherapy is appropriate for fit patients with disseminated disease, constitutional symptoms and/or signs of high-grade transformation.[74] It is recognised that R-CVP and R-CHOP, both commonly used in follicular lymphoma, may be treatment options in Australia for SMZL; however, the largest body of data is for R-COMP (rituximab with cyclophosphamide, vincristine, non-pegylated liposomal doxorubicin (Myocet) and prednisone) used in the prospective FIL trial.[74] Fifty-one patients achieved an ORR of 84%, 6-year PFS of 54% and OS of 72%, although there was 26% grade >3 neutropenia and 8% grade >3 infections.[74] The combination of rituximab with bendamustine has never been studied in a dedicated trial of SMZL, but there were sufficient numbers of patients with MZL overall in both the BRIGHT[29] and STiL[28] studies to identify excellent response rates and possibly comparable PFS rates with BR, as with R-CVP and R-CHOP. The use of rituximab maintenance for 2 years following initial treatment with BR in both nodal and SMZL has been shown to significantly increase PFS (but not OS) compared to no maintenance (HR 0.35, 95% CI 0.17–0.76, $P = 0.008$) in the STiL NHL7-2008 MAINTAIN trial.[80]

Rituximab monotherapy has been associated with ORRs of 90–100% in several retrospective studies, with approximately half the patients obtaining a CR (normalisation of both blood counts and splenomegaly);[75] however, it is not currently reimbursed as monotherapy for splenic MZL in Australia or New Zealand.

Conclusion

Less frequently encountered subtypes of NHL, which include MCL and the three MZL subtypes (MALT lymphoma, nodal MZL and SMZL), are distinct clinico-pathologic entities and require specific diagnostic and therapeutic considerations. Most patients with MCL have advanced stage disease at diagnosis, with age and fitness of the patient influencing treatment approach. High dose cytarabine-containing chemoimmunotherapy and ASCT result in high response rates and durable remissions (median PFS 5–7 years) in younger/fitter patients, while older patients may be offered less intensive regimens such as BR.

MZLs share several overlapping pathologic features with other indolent B-cell lymphomas and present diagnostic challenges. Infectious and autoimmune aetiologies should be considered and, critically, gastric MALT subtype lymphoma is often associated with *H. pylori* infection – in which case eradication therapy is frequently successful. Nodal MZL and splenic MZL are both associated with hepatitis C in a minority of cases.

Other entity-specific considerations include the role of splenectomy in SMZL. Systemic treatments for MZLs share similarities and depend on whether disease is localised or advanced, symptomatic or not, and patient age and fitness. Specific evidence for each entity is limited as patients are often included with follicular lymphoma in prospective studies. For localised disease, radiation therapy is frequently used. Recognising the indolent biology, a watch and wait approach is usually appropriate in asymptomatic advanced stage patients. When treatment is indicated, common approaches include rituximab monotherapy where applicable and available, and chemoimmunotherapy with BR or R-CVP/R-CHOP regimens. Well designed clinical trials evaluating novel approaches in these specific entities are needed.

© 2019 Royal Australasian College of Physicians

References

1 Talaulikar D, Tam CS, Joshua D, Ho JP, Szer J, Quach H *et al*. Treatment of patients with Waldenstrom macroglobulinaemia: clinical practice guidelines from the Myeloma Foundation of Australia Medical and Scientific Advisory Group. *Intern Med J* 2017; **47**: 35–49.

2 Australian Institute of Health and Welfare. *Cancer in Australia 2017. Cancer Series No. 101. Cat. No. CAN 100*. Canberra: AIHW; 2017.

3 van Leeuwen MT, Turner JJ, Joske DJ, Falster MO, Srasuebkul P, Meagher NS *et al*. Lymphoid neoplasm incidence by WHO subtype in Australia 1982–2006. *Int J Cancer* 2014; **135**: 2146–56.

4 Dreyling M, Campo E, Hermine O, Jerkeman M, Le Gouill S, Rule S *et al*. Newly diagnosed and relapsed mantle cell lymphoma: ESMO clinical practice guidelines for diagnosis, treatment and follow-up. *Ann Oncol* 2017; **28**: iv62–71.

5 Abrahamsson A, Albertsson-Lindblad A, Brown PN, Baumgartner-Wennerholm S, Pedersen LM, D'Amore F *et al*. Real world data on primary treatment for mantle cell lymphoma: a Nordic lymphoma group observational study. *Blood* 2014; **124**: 1288–95.

6 Cheah CY, Seymour JF, Wang ML. Mantle cell lymphoma. *J Clin Oncol* 2016; **34**: 1256–69.

7 Martin P, Leonard J. Is there a role for watch and wait in patients with mantle cell lymphoma? *Semin Hematol* 2011; **48**: 189–93.

8 Hu Z, Sun Y, Schlette EJ, Tang G, Li S, Xu J *et al*. CD200 expression in mantle cell lymphoma identifies a unique subgroup of patients with frequent IGHV mutations, absence of SOX11 expression, and an indolent clinical course. *Mod Pathol* 2018; **31**: 327–36.

9 Cheson BD, Fisher RI, Barrington SF, Cavalli F, Schwartz LH, Zucca E *et al*. Recommendations for initial evaluation, staging, and response assessment of Hodgkin and non-Hodgkin lymphoma: the Lugano classification. *J Clin Oncol* 2014; **32**: 3059–68.

10 Swerdlow SH, Campo E, Harris NL, Jaffe ES, Pileri S, Stein H *et al*. *WHO Classification of Tumours of Haematopoietic and Lymphoid Tissues*, 4th edn. Lyon, France: IARC Publications; 2017.

11 Mozos A, Royo C, Hartmann E, De Jong D, Baro C, Valera A *et al*. SOX11 expression is highly specific for mantle cell lymphoma and identifies the cyclin D1-negative subtype. *Haematologica* 2009; **94**: 1555–62.

12 Hoster E, Rosenwald A, Berger F, Bernd HW, Hartmann S, Loddenkemper C *et al*. Prognostic value of Ki-67 index, cytology, and growth pattern in mantle-cell lymphoma: results from randomized trials of the European mantle cell lymphoma network. *J Clin Oncol* 2016; **34**: 1386–94.

13 Dabaja BS, Zelenetz AD, Ng AK, Tsang RW, Qi S, Allen PK *et al*. Early-stage mantle cell lymphoma: a retrospective analysis from the International Lymphoma Radiation Oncology Group (ILROG). *Ann Oncol* 2017; **28**: 2185–90.

14 Martin P, Chadburn A, Christos P, Weil K, Furman RR, Ruan J *et al*. Outcome of deferred initial therapy in mantle-cell lymphoma. *J Clin Oncol* 2009; **27**: 1209–13.

15 Geisler CH, Kolstad A, Laurell A, Andersen NS, Pedersen LB, Jerkeman M *et al*. Long-term progression-free survival of mantle cell lymphoma after intensive front-line immunochemotherapy with in vivo-purged stem cell rescue: a nonrandomized phase 2 multicenter study by the Nordic lymphoma group. *Blood* 2008; **112**: 2687–93.

16 Hermine O, Hoster E, Walewski J, Bosly A, Stilgenbauer S, Thieblemont C *et al*. Addition of high-dose cytarabine to immunochemotherapy before autologous stem-cell transplantation in patients aged 65 years or younger with mantle cell lymphoma (MCL Younger): a randomised, open-label, phase 3 trial of the European mantle cell lymphoma network. *Lancet* 2016; **388**: 565–75.

17 Le Gouill S, Thieblemont C, Oberic L, Moreau A, Bouabdallah K, Dartigeas C *et al*. Rituximab after autologous stem-cell transplantation in mantle-cell lymphoma. *N Engl J Med* 2017; **377**: 1250–60.

18 Romaguera JE, Fayad L, Rodriguez MA, Broglio KR, Hagemeister FB, Pro B *et al*. High rate of durable remissions after treatment of newly diagnosed aggressive mantle-cell lymphoma with rituximab plus hyper-CVAD alternating with rituximab plus high-dose methotrexate and cytarabine. *J Clin Oncol* 2005; **23**: 7013–23.

19 Chihara D, Cheah CY, Westin JR, Fayad LE, Rodriguez MA, Hagemeister FB *et al*. Rituximab plus hyper-CVAD alternating with MTX/Ara-C in patients with newly diagnosed mantle cell lymphoma: 15-year follow-up of a phase II study from the MD Anderson Cancer Center. *Br J Haematol* 2016; **172**: 80–8.

20 Chen R, Li H, Bernstein SH, Rimsza LM, Forman S, Constine LS *et al*. Results of a randomized phase II trial of R-HCVAD versus R-bendamustine followed by autologous stem cell transplantation for patients with mantle cell lymphoma: US Intergroup S1106. *Hematol Oncol* 2015; **33**: 132.

21 Dreyling M, Lenz G, Hoster E, Van Hoof A, Gisselbrecht C, Schmits R *et al*. Early consolidation by myeloablative radiochemotherapy followed by autologous stem cell transplantation in first remission significantly prolongs progression-free survival in mantle-cell lymphoma: results of a prospective randomized trial of the European MCL Network. *Blood* 2005; **105**: 2677–84.

22 Robinson S, Dreger P, Caballero D, Corradini P, Geisler C, Ghielmini M *et al*. The EBMT/EMCL consensus project on the role of autologous and allogeneic stem cell transplantation in mantle cell lymphoma. *Leukemia* 2015; **29**: 464–73.

23 Fenske TS, Zhang MJ, Carreras J, Ayala E, Burns LJ, Cashen A *et al*. Autologous or reduced-intensity conditioning allogeneic hematopoietic cell transplantation for chemotherapy-sensitive mantle-cell lymphoma: analysis of transplantation timing and modality. *J Clin Oncol* 2014; **32**: 273–81.

24 Cruz JG, Martino R, Balsalobre P, Heras I, Piñana JL, Serrano D *et al*. Long-term results of fludarabine/melphalan as a reduced-intensity conditioning regimen in mantle cell lymphoma: the GELTAMO experience. *Ther Adv Hematol* 2011; **2**: 5–10.

25 Kruger WH, Hirt C, Basara N, Sayer HG, Behre G, Fischer T *et al*. Allogeneic stem cell transplantation for mantle cell lymphoma – final report from the prospective trials of the East German Study Group Haematology/Oncology (OSHO). *Ann Hematol* 2014; **93**: 1587–97.

© 2019 Royal Australasian College of Physicians

26 Evens AM, Winter JN, Hou N, Nelson BP, Rademaker A, Patton D *et al*. A phase II clinical trial of intensive chemotherapy followed by consolidative stem cell transplant: long-term follow-up in newly diagnosed mantle cell lymphoma. *Br J Haematol* 2008; **140**: 385–93.

27 Eskelund CW, Kolstad A, Jerkeman M, Raty R, Laurell A, Eloranta S *et al*. 15-Year follow-up of the second Nordic mantle cell lymphoma trial (MCL2): prolonged remissions without survival plateau. *Br J Haematol* 2016; **175**: 410–8.

28 Rummel MJ, Niederle N, Maschmeyer G, Banat GA, von Grunhagen U, Losem C *et al*. Bendamustine plus rituximab versus CHOP plus rituximab as first-line treatment for patients with indolent and mantle-cell lymphomas: an open-label, multicentre, randomised, phase 3 non-inferiority trial. *Lancet* 2013; **381**: 1203–10.

29 Flinn I, Jagt R, Chang J, Wood P, Hawkins T, MacDonald D *et al*. First-line treatment of iNHL or MCL patients with BR or R-CHOP/R-CVP: results of the BRIGHT 5-year follow-up study. *Hematol Oncol* 2017; **35**: 140–1.

30 Kluin-Nelemans HC, Hoster E, Hermine O, Walewski J, Trneny M, Geisler CH *et al*. Treatment of older patients with mantle-cell lymphoma. *N Engl J Med* 2012; **367**: 520–31.

31 Rummel MJKW, Goerner M, Soeling U, Lange E, Hertenstein B *et al*. Two years rituximab maintenance vs. observation after first-line treatment with bendamustine plus rituximab (B-R) in patients with mantle cell lymphoma: first results of a prospective, randomized, multicenter phase II study (a subgroup study of the StiL NHL7-2008 MAINTAIN trial). *J Clin Oncol* 2016; **34**: 7503.

32 Visco C, Chiappella A, Nassi L, Patti C, Ferrero S, Barbero D *et al*. Rituximab, bendamustine, and low-dose cytarabine as induction therapy in elderly patients with mantle cell lymphoma: a multicentre, phase 2 trial from Fondazione Italiana Linfomi. *Lancet Haematol* 2017; **4**: e15–23.

33 Ratnasingam S, Gilbertson M, McQuilten Z, Htun KT, Grigoriadis G, Htet SM *et al*. Improved survival of older patients with mantle cell lymphoma (MCL) with front-line cytarabine-based immunochemotherapy. *Blood* 2016; **128**: 2965.

34 Laurell A, Kolstad A, Jerkeman M, Raty R, Geisler CH. High dose cytarabine with rituximab is not enough in first-line treatment of mantle cell lymphoma with high proliferation: early closure of the Nordic lymphoma group mantle cell lymphoma 5 trial. *Leuk Lymphoma* 2014; **55**: 1206–8.

35 Robinson SP, Boumendil A, Finel H, Peggs KS, Chevallier P, Sierra J *et al*. Long-term outcome analysis of reduced-intensity allogeneic stem cell transplantation in patients with mantle cell lymphoma: a retrospective study from the EBMT lymphoma working party. *Bone Marrow Transplant* 2018; **53**: 617–24.

36 Rummel M, Kaiser U, Balser C, Stauch M, Brugger W, Welslau M *et al*. Bendamustine plus rituximab versus fludarabine plus rituximab for patients with relapsed indolent and mantle-cell lymphomas: a multicentre, randomised, open-label, non-inferiority phase 3 trial. *Lancet Oncol* 2016; **17**: 57–66.

37 Rule S, Dreyling M, Goy A, Hess G, Auer R, Kahl B *et al*. Outcomes in 370 patients with mantle cell lymphoma treated with ibrutinib: a pooled analysis from three open-label studies. *Br J Haematol* 2017; **179**: 430–8.

38 Tam CS, Anderson MA, Pott C, Agarwal R, Handunnetti S, Hicks RJ *et al*. Ibrutinib plus venetoclax for the treatment of mantle-cell lymphoma. *New Engl J Med* 2018; **378**: 1211–23.

39 Reid R, Friedberg JW. Management of marginal zone lymphoma. *Oncology (Williston Park)* 2013; **27**: 840–4.

40 Sriskandarajah P, Dearden CE. Epidemiology and environmental aspects of marginal zone lymphomas. *Best Pract Res Clin Haematol* 2017; **30**: 84–91.

41 Zucca E, Bertoni F. The spectrum of MALT lymphoma at different sites: biological and therapeutic relevance. *Blood* 2016; **127**: 2082–92.

42 Zucca E, Copie-Bergman C, Ricardi U, Thieblemont C, Raderer M, Ladetto M. Gastric marginal zone lymphoma of MALT type: ESMO clinical practice guidelines for diagnosis, treatment and follow-up. *Ann Oncol* 2013; **24**: vi144–8.

43 Raderer M, Wöhrer S, Streubel B, Troch M, Turetschek K, Jäger U *et al*. Assessment of disease dissemination in gastric compared with extragastric mucosa-associated lymphoid tissue lymphoma using extensive staging: a single-center experience. *J Clin Oncol* 2006; **24**: 3136–41.

44 Thieblemont C, Cascione L, Conconi A, Kiesewetter B, Raderer M, Gaidano G *et al*. A MALT lymphoma prognostic index. *Blood* 2017; **130**: 1409–17.

45 Network NCC. National Comprehensive Cancer Network (NCCN) Guidelines – B-Cell Lymphomas 2017; Version 6 (15/11/17).

46 Ryu KD, Kim GH, Park SO, Lee KJ, Moon JY, Jeon HK *et al*. Treatment outcome for gastric mucosa-associated lymphoid tissue lymphoma according to *Helicobacter pylori* infection status: a single-center experience. *Gut Liver* 2014; **8**: 408–14.

47 Ferreri AJ, Cecchetti C, Kiesewetter B, Sassone M, Calimeri T, Perrone S *et al*. Clarithromycin as a "repurposing drug" against lymphomas: safety and efficacy profiles in 55 patients with extranodal marginal zone lymphoma (EMZL). *Hematol Oncol* 2017; **35**: 2.

48 Goda JS, Gospodarowicz M, Pintilie M, Wells W, Hodgson DC, Sun A *et al*. Long-term outcome in localized extranodal mucosa-associated lymphoid tissue lymphomas treated with radiotherapy. *Cancer* 2010; **116**: 3815–24.

49 Zucca E, Conconi A, Laszlo D, Lopez-Guillermo A, Bouabdallah R, Coiffier B *et al*. Addition of rituximab to chlorambucil produces superior event-free survival in the treatment of patients with extranodal marginal-zone B-cell lymphoma: 5-year analysis of the IELSG-19 randomized study. *J Clin Oncol* 2013; **31**: 565–72.

50 Kiesewetter B, Raderer M. Antibiotic therapy in nongastrointestinal MALT lymphoma: a review of the literature. *Blood* 2013; **122**: 1350–7.

51 Ferreri AJM, Ponzoni M, Dognini GP, Du MQ, Doglioni C, Radford J *et al*. Bacteria-eradicating therapy for ocular adnexal MALT lymphoma: questions for an open international prospective trial. *Ann Oncol* 2006; **17**: 1721–2.

52 Zucca E, Stathis A, Bertoni F. The management of non-gastric MALT lymphomas. *Oncol J* 2014; **28**: 86–93.

53 Salar A, Domingo-Domenech E, Panizo C, Nicolas C, Bargay J, Muntanola A *et al*. First-line response-adapted treatment with the combination of bendamustine and

© 2019 Royal Australasian College of Physicians

rituximab in patients with mucosa-associated lymphoid tissue lymphoma (MALT2008-01): a multicentre, single-arm, phase 2 trial. *Lancet Haematol* 2014; **1**: e104–11.
54 Kiesewetter B, Troch M, Dolak W, Müllauer L, Lukas J, Zielinski CC *et al*. A phase II study of lenalidomide in patients with extranodal marginal zone B-cell lymphoma of the mucosa associated lymphoid tissue (MALT lymphoma). *Haematologica* 2013; **98**: 353–6.
55 Conconi A, Martinelli G, Lopez-Guillermo A, Zinzani PL, Ferreri AJ, Rigacci L *et al*. Clinical activity of bortezomib in relapsed/refractory MALT lymphomas: results of a phase II study of the international extranodal lymphoma study group (IELSG). *Ann Oncol* 2011; **22**: 689–95.
56 Thieblemont C, Molina T, Davi F. Optimizing therapy for nodal marginal zone lymphoma. *Blood* 2016; **127**: 2064–71.
57 Pileri S, Ponzoni M. Pathology of nodal marginal zone lymphomas. *Best Pract Res Clin Haematol* 2017; **30**: 50–5.
58 Conconi A, Franceschetti S, Aprile von Hohenstaufen K, Margiotta-Casaluci G, Stathis A, Moccia AA *et al*. Histologic transformation in marginal zone lymphomas. *Ann Oncol* 2015; **26**: 2329–35.
59 Alderuccio JP, Desai A, Gallastegui Crestani N, Ramdial J, Kimble EL, De La Fuente MI *et al*. Outcomes in patients with marginal zone lymphomas undergoing transformation to high-grade lymphomas. *J Clin Oncol* 2018; **36**: 7559.
60 Arcaini L, Paulli M, Boveri E, Vallisa D, Bernuzzi P, Orlandi E *et al*. Splenic and nodal marginal zone lymphomas are indolent disorders at high hepatitis C virus seroprevalence with distinct presenting features but similar morphologic and phenotypic profiles. *Cancer* 2004; **100**: 107–15.
61 van den Brand M, van Krieken JH. Recognizing nodal marginal zone lymphoma: recent advances and pitfalls. A systematic review. *Haematologica* 2013; **98**: 1003–13.
62 Olszewski AJ, Castillo JJ. Survival of patients with marginal zone lymphoma: analysis of the surveillance, epidemiology, and end results database. *Cancer* 2013; **119**: 629–38.
63 Starr AG, Caimi PF, Fu P, Massoud MR, Meyerson H, Hsi ED *et al*. Dual institution experience of nodal marginal zone lymphoma reveals excellent long-term outcomes in the rituximab era. *Br J Haematol* 2016; **175**: 275–80.
64 Martinez-Lopez A, Curiel-Olmo S, Mollejo M, Cereceda L, Martinez N, Montes-Moreno S *et al*. MYD88 (L265P) somatic mutation in marginal zone B-cell lymphoma. *Am J Surg Pathol* 2015; **39**: 644–51.
65 Heilgeist A, McClanahan F, Ho AD, Witzens-Harig M. Prognostic value of the follicular lymphoma international prognostic index score in marginal zone lymphoma: an analysis of clinical presentation and outcome in 144 patients. *Cancer* 2013; **119**: 99–106.
66 Arcaini L, Besson C, Frigeni M, Fontaine H, Goldaniga M, Casato M *et al*. Interferon-free antiviral treatment in B-cell lymphoproliferative disorders associated with hepatitis C virus infection. *Blood* 2016; **128**: 2527–32.
67 Kelaidi C, Rollot F, Park S, Tulliez M, Christoforov B, Calmus Y *et al*. Response to antiviral treatment in hepatitis C virus-associated marginal zone lymphomas. *Leukemia* 2004; **18**: 1711–6.
68 Kang HJ, Kim WS, Kim SJ, Lee JJ, Yang DH, Kim JS *et al*. Phase II trial of rituximab plus CVP combination chemotherapy for advanced stage marginal zone lymphoma as a first-line therapy: consortium for improving survival of lymphoma (CISL) study. *Ann Hematol* 2012; **91**: 543–51.
69 Brown JR, Friedberg JW, Feng Y, Scofield S, Phillips K, Dal Cin P *et al*. A phase 2 study of concurrent fludarabine and rituximab for the treatment of marginal zone lymphomas. *Br J Haematol* 2009; **145**: 741–8.
70 Ferrario A, Pulsoni A, Olivero B, Rossi G, Vitolo U, Tedeschi A *et al*. Fludarabine, cyclophosphamide, and rituximab in patients with advanced, untreated, indolent B-cell nonfollicular lymphomas: phase 2 study of the Italian Lymphoma Foundation. *Cancer* 2012; **118**: 3954–61.
71 Laribi K, Tempescul A, Ghnaya H, Denizon N, Besancon A, Anghel A *et al*. The bendamustine plus rituximab regimen is active against primary nodal marginal zone B-cell lymphoma. *Hematol Oncol* 2017; **35**: 536–41.
72 Shimoni A. The role of stem-cell transplantation in the treatment of marginal zone lymphoma. *Best Pract Res Clin Haematol* 2017; **30**: 166–71.
73 Spina V, Khiabanian H, Messina M, Monti S, Cascione L, Bruscaggin A *et al*. The genetics of nodal marginal zone lymphoma. *Blood* 2016; **128**: 1362–73.
74 Arcaini L, Rossi D, Paulli M. Splenic marginal zone lymphoma: from genetics to management. *Blood* 2016; **127**: 2072–81.
75 Kalpadakis C, Pangalis GA, Angelopoulou MK, Vassilakopoulos TP. Treatment of splenic marginal zone lymphoma. *Best Pract Res Clin Haematol* 2017; **30**: 139–48.
76 Swerdlow SH, Kuzu I, Dogan A, Dirnhofer S, Chan JK, Sander B *et al*. The many faces of small B cell lymphomas with plasmacytic differentiation and the contribution of MYD88 testing. *Virchows Archiv* 2016; **468**: 259–75.
77 Santos TSd, Tavares RS, Farias DLCd. Splenic marginal zone lymphoma: a literature review of diagnostic and therapeutic challenges. *Rev Bras Hematol Hemoter* 2017; **39**: 146–54.
78 Piris MA, Onaindia A, Mollejo M. Splenic marginal zone lymphoma. *Best Pract Res Clin Haematol* 2017; **30**: 56–64.
79 Kanhutu K, Jones P, Cheng AC, Grannell L, Best E, Spelman D. Spleen Australia guidelines for the prevention of sepsis in patients with asplenia and hyposplenism in Australia and New Zealand. *Intern Med J* 2017; **47**: 848–55.
80 Rummel MJ, Koenigsmann M, Chow KU, Knauf W, Lerchenmuller CA *et al*. Two years rituximab maintenance vs. observation after first line treatment with bendamustine plus rituximab (B-R) in patients with marginal zone lymphoma (MZL): results of a prospective, randomized, multicenter phase 2 study (the StiL NHL7-2008 MAINTAIN trial). *J Clin Oncol* 2018; **36**: 7515.

© 2019 Royal Australasian College of Physicians